CASE REPORT

Aortic Stenting and Thoracolumbar Fusion after Traumatic ASIA A Thoracic Dislocation

Hassan Fadel,[1] Neil Klinger,[1] Patrick Beer,[3] Farzana Tariq,[1] Chelsea Smith,[3] Susan Seman,[2] Justin Hugelier,[1] Michael Zwillman, [4] Marc Moisi,[1] Robert Johnson[1]

[1]Department of Neurosurgery, Wayne State University School of Medicine, Detroit, Michigan
[2]Department of General Surgery, Michigan State University College of Osteopathic Medicine, Detroit, Michigan
[3]Department of Trauma Surgery/Critical Care, Michigan State University College of Osteopathic Medicine, Detroit, Michigan
[4]Department of Anesthesia and Critical Care, Houston Methodist Willowbrook, Houston, TX

http:thespinescholar.com
https:doi.org/10.26632/ss.7.2017.1.2

Key Words: ankylosing spondylitis, thoracic dislocation, cord transaction, aortic endovascular stent graft, EVAR, thoracic fusion

ABSTRACT

We present a case of a 65-year-old woman with a history of ankylosing spondylitis who suffered from thoracic fracture dislocation and aortic compression after a fall. This is one of very few reported cases describing treatment of both these entities. An aortic endograft device was placed upon presentation to achieve hemodynamic stability. After several days in the intensive care unit stabilizing the patient's several medical comorbidities, the spine was subsequently reapproximated and fused to prevent further neurological injury. Patients with AS are at increased risk of both vertebral fractures and aortic trauma, therefore, high clinical suspicion and a through work up should be carried out to address these complications earlier and intervene accordingly. Although such complex presentations are rare, they pose imminent threat to the patient and a significant therapeutic challenge to providers. The presented case serves as an example of multidisciplinary treatment leading to a satisfactory patient outcome. Spine Scholar 1:84-89, 2017

INTRODUCTION

Ankylosing spondylitis (AS) is a progressive inflammatory rheumatological disease that predominantly affects the axial skeleton. AS, a prototypic seronegative spondyloarthropathy, is characterized by inflammation and osteoproliferation of the spinal joints and ligaments, leading to progressive fusion and kyphosis of the spine. The fused and rigid spine assumes the biomechanics of a long bone and the resultant lever arms predispose AS patients to spinal fractures (Westerveld et al., 2009). The inflammation throughout the vertebral column also results in loss of bone mineral density, with osteoporosis affecting a large proportion of AS patients (Feldtkeller et al., 2006; Vosse et al., 2009; Klingberg et al., 2012; Sambrook et al., 2012; Ulu et al., 2014; Werner et al., 2016). Increased rigidity of the spine coupled with poor bone mineralization further increases the risk of vertebral fractures in AS patients exposed to otherwise minor trauma (Cooper et al., 1994; Hitchon et al., 2002; Baek et al., 2005; Feldtkeller et al., 2006; Montala et al., 2011; Klingberg et al., 2012; Briot et al., 2015). With compromised ligaments leading to the loss of elasticity and osteoporosis leading to weakened bone structure, AS vertebral fractures are often highly unstable and might lead to devastating neurologic and vascular complications.

The incidence of vertebral fractures in patients with AS has been estimated to be between three to four times that of the general population (Cooper et al., 1994; Vosse et al., 2009). Although the age at time of fracture has been shown to be highly variable, multiple studies have found that the majority of vertebral fractures in AS patients occur in men, with cervical fractures occurring most commonly (Caron et al., 2010; Lukasiewicz et al., 2016). The increased rate of vertebral fractures is matched by an increased incidence of spinal cord injury (SCI), with AS patients having an 11.4 times greater risk of SCI than the general population (Alaranta et al., 2002). Therefore, an elevated level of clinical suspicion for vertebral injury is warranted when AS patients present with neck or back pain, even in absence of a history of notable trauma.

The authors report a case of a 65-year-old female AS patient who presented with a thoracic spine fracture-dislocation after a ground level fall with associated spinal column impingement of the aorta requiring an endovascular stent graft.

Case Presentation

The patient is a 65-year-old African American female with a past medical history significant for hypertension, congestive heart failure with an ejection fraction of 35-40%, obesity, diabetes mellitus, chronic obstructive pulmonary disease, and ankylosing spondylitis who presented to the emergency department after sustaining a ground level fall while under alcohol intoxication. On presentation, the patient was experiencing headache, neck pain, and paresthesias in her bilateral lower extremities. Initial trauma evaluation was significant for lack of rectal tone and paraplegia. While transporting the patient to the CT scanner, the patient suddenly became hypotensive to 50/30 mmHg, bradycardic to 50 bpm, and hypoxic to 70% on non-rebreather mask. She was emergently intubated and started on aggressive fluid resuscitation.

Her Initial CT head was negative for acute intracranial processes. Ossification of the anterior longitudinal ligament was visualized throughout the cervical spine (**Fig. 1**) as is typical of AS, without any evidence of acute fracture or deformity. CT of the thoracic spine showed a comminuted Chance type fracture of the T11 vertebral body and posterior elements along with anterior dislocation of distal T11 components with possible spinal cord transection and surrounding hematoma (**Fig. 2A**). She was also found to have bilateral comminuted 11th rib fractures. CTA of the thorax and abdomen revealed compression of the thoracic aorta posteriorly from the anteriorly displaced Chance fracture of T11 vertebral body without evidence of laceration or injury (**Fig. 2B**). Bilateral hemothorax with pneumothoraces was also present, as was compressive atelectasis and contusions of bilateral lower lobes. Bilateral chest tubes were placed by the trauma team.

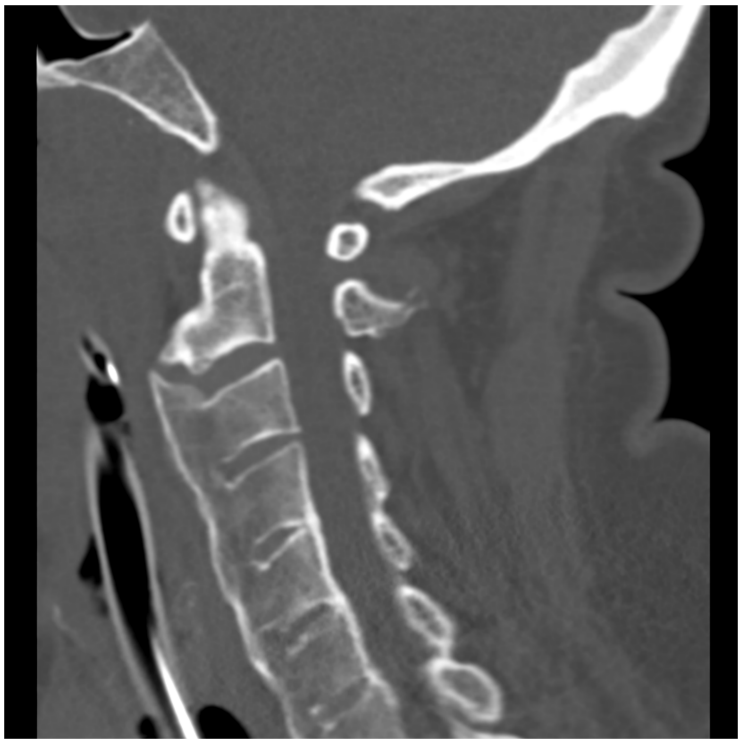

Figure 1: Sagittal computed tomography of the cervical spine showing typical bony features of ankylosing spondylitis. There is heavy ossification of the anterior longitudinal ligament, that has led to fusion of the vertebral bodies in the cervical spine.

Figure 2: (A) Sagittal computed tomography angiography showing the Chance fracture at T11 with anterior dislocation of the caudal spinal column and aortic compression. (B) Axial computed tomography angiography scan at vertebral level T10 showing normal caliber of the aorta. (C) Axial computed tomography angiography scan at the inferior portion of T11 showing compression of the aorta with over 2-fold decrease in cross-sectional area.

Due to hemodynamic instability caused by aortic impingement by the dislocated spinal column, the patient underwent percutaneous endovascular aortic repair (EVAR). The patient was placed in the supine position and under general endotracheal anesthesia, the left femoral artery was accessed with a micropuncture needle and upsized to a 6-French sheath. A 0.035 inch Lunderquist wire and 20-French sheath was positioned. A marking pigtail 4-French catheter was placed into the thoracic aorta and an aortogram was performed. The GORE TAG endograft device (26 tapered to 21) was then deployed over the vertebral fracture site. Intraoperative angiography demonstrated complete patency without endoleak or other complication. The sheath and wire were subsequently removed and the right groin site was closed with a ProGlide device without complication. The patient was transferred to the ICU in stable condition. The following day, the patient underwent bronchoscopy due to episode of bradycardia and oxygen desaturation and was found to have a mucous plug.

Five days after initial presentation, the patient was taken back to the operating room for correction and fusion of the dislocated thoracic spine. The patient was placed in the prone position. C-arm fluoroscopy was used to confirm the appropriate thoracic level. A midline incision was made spanning T6 to L4. Pedicle screws were placed at T7, T8, T9, T10, T12, L1, L2, and L3 under O-arm guidance. The rods were then contoured to the appropriate anatomic curvature and reduction screw heads were carefully tightened to reduce the fracture dislocation and re-align the spinal column. The fracture defect anteriorly was debrided of blood products and granulation tissue. Bone was harvested from the fracture dislocation at T10 and T11, denuded of its soft tissues, morcellated into corticocancellous chips, and packed into the anterior column to complete the T11 interbody fusion construct (**Fig. 3**). The patient tolerated the procedure well and was taken to the recovery room in hemodynamically stable condition. The patient's hospital course was complicated by ventilator dependency due to inability to clear secretions for which patient underwent tracheostomy and percutaneous endoscopic gastrostomy tube place prior to being discharge with a TLSO brace to a rehabilitation facility 20 days after her initial presentation.

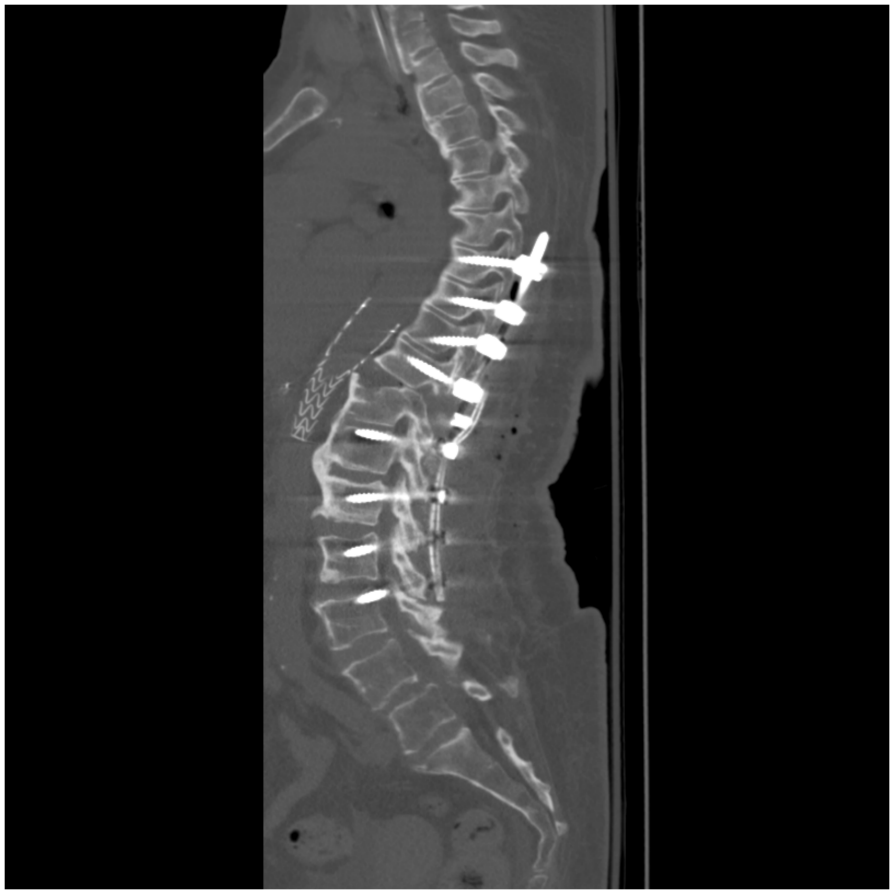

Figure 3: Sagittal computed tomography showing the fusion construct from T7 to L3. Bilateral pedicle screws were placed at T7, T8, T9, T10, T12, L1, L2, and L3, and mixture of morcelated bone and Vivien allograft was packed along the anterior column, spinous processes, laminae, and facet joints. The aortic endograft device is partially visualized spanning the T11 dislocation site.

DISCUSSION

Ankylosing spondylitis is a chronic inflammatory rheumatic disease that leads to progressive fusion and kyphosis of the spine. Ongoing inflammation leads to a significant loss of bone mineral density of the vertebral column. Therefore, patients with AS have weakened and fused vertebrae susceptible to highly unstable fractures from otherwise minimal trauma. In fact, multiple reports have suggested that traumatic fractures are three to four times more likely to develop in AS patients than the general population (Cooper et al., 1994; Vosse et al., 2009). Data also suggest that fractures are more likely to occur at the cervical level (53%) than at the thoracic (41.9%) or lumbar (18.2%) (Lukasiewicz et al., 2016). A recent meta-analysis of published case series has shown that more than half of AS vertebral fractures are treated surgically with posterior fixation, most often indicated due to neurological complications or unstable fracture configurations. Conservative treatment in the form of cervical traction or collar is used in the setting of high surgical risk or patient refusal of surgical intervention (Westerveld et al., 2009). AS is a progressive and chronic disease with lifelong treatment strategies utilizing a combination of pharmacologic therapy, rehabilitation, and surgical interventions. Together, these help relieve symptoms, maintain daily function, and prevent spinal deformity and injury (Ward et al., 2016).

Of the extra-articular manifestations of AS, inflammation of the aorta can directly complicate vertebral fractures, particularly of the thoracolumbar region. Aortitis has been shown to cause fibrotic and proliferative changes in the aorta resulting in adhesion to the ossified anterior longitudinal ligament (Fazl et al., 1981; Schaberg, 1986; Weatherley et al., 1988; Savolaine et al., 1991; Tiesenhausen et al., 2001; Lifshutz et al., 2005). The inflamed, fibrosed and adherent aorta is thus weaker and more susceptible to any direct or blunt vertebral trauma (Lifshutz et al., 2005). Given that non-pathological vertebral fractures pose a significant and potentially life-threatening risk of aortic trauma (Arajarvi et al., 1989; Stambough et al., 1989; Bakker et al., 1996; Coimbra et al., 1996; Inaba et al., 2001; Domenicucci et al., 2011; Bashir et al., 2013; Chock et al., 2015; Yoshioka et al., 2016; Cultrera et al., 2017; Omori et al., 2017), AS patients with comorbid vertebral fractures are therefore at heightened risk of aortic dissection,

psuedoaneurysm, and encroachment (Fazl et al., 1981; Schaberg, 1986; Weatherley et al., 1988; Savolaine et al., 1991; Tiesenhausen et al., 2001; Lifshutz et al., 2005). Although rare, such presentations pose a significant challenge to providers and require multidisciplinary treatment.

In a retrospective study conducted by Caron et al. (2010) , the majority of spine fractures in AS patients were hyperextension fractures through the vertebral body. The incidence of spinal cord injury (SCI) in the studied population was 58%, with the majority of patients assigned a documented American Spinal Injury Association (ASIA) grade at admission (Caron et al., 2010). These findings complement another study by Alaranta et al. in 2002, that found patients with AS to have an 11.4 times greater risk of SCI than the general population and that the majority of SCIs are caused by low energy trauma, with a fall from a standing or sitting position the most commonly noted cause of patient presentation (Alaranta et al., 2002). Our patient also suffered a traumatic fall that led to an ASIA A (no sensory or motor function (Kirshblum et al., 2011)) thoracic dislocation. Additionally, she was found to have aortic compression that caused hemodynamic instability and required immediate intervention. As detailed above, a GORE TAG endovascular stent graft was used to stent the aorta to help alleviate this impingement. To the authors knowledge, there were no reports in the literature describing traumatic dislocation requiring concurrent treatment of aortic compression while this report was being drafted. However, a literature review prior to submission uncovered similar work by Cultrera et al. in 2017. They report of a compression-distraction fracture of the 6th and 7th thoracic vertebrae with a fracture fragment dislocated in close proximity to the descending thoracic aorta. Similarly, to our case, their patient was first treated with a trans-femoral stent-graft into the thoracic aorta followed by stabilization of the dorsal spine via T3-T10 fixation. However, pertinent differences between the two cases exist in that, as noted previously, our patient presented with symptoms of devastating SCI and cardiovascular instability, while the report by the Cultera et al. described a patient who at presentation had no neurological deficits and no noted cardiovascular complications (Cultrera et al., 2017). Also, the aortic encroachment seen in our patient was due to severe spinal fracture and dislocation, as compared to the fracture-displacement injury. Further review of the literature shows several reports of unstable vertebral fractures with concurrent or potential aortic involvement (Bakker et al., 1996; Domenicucci et al., 2011; Chock et al., 2015; Yoshioka et al., 2016; Omori et al., 2017), though they do not describe traumatic fracture-dislocation with concomitant aortic encroachment. The unique case presented here demonstrates implementation of aortic stabilization in the setting of acute compression by the vertebral column with spinal cord transection, and subsequent posterior fixation of the vertebral fracture-dislocation in a patient with ankylosing spondylitis.

REFERENCES

Alaranta H, Luoto S, Konttinen YT, 2002. Traumatic spinal cord injury as a complication to ankylosing spondylitis. An extended report. Clin Exp Rheumatol 20(1):66-8.

Arajarvi E, Santavirta S, Tolonen J, 1989. Aortic ruptures in seat belt wearers. J Thorac Cardiovasc Surg 98:355-61.

Baek HJ, Kang SW, Lee YJ, Shin KC, Lee EB, Yoo CD, Song YW, 2005. Osteopenia in men with mild and severe ankylosing spondylitis. Rheumatol Int 26(1):30-4. 10.1007/s00296-004-0516-3

Bakker FC, Patka P, Haarman HJ, 1996. Combined repair of a traumatic rupture of the aorta and anterior stabilization of a thoracic spine fracture: a case report. J Trauma 40:128-9.

Bashir M, McWilliams RG, Desmond M, Kuduvalli M, Oo A, Field M, 2013. Blunt aortic injury secondary to fragmented tenth thoracic vertebral body. Ann Thorac Surg 95(6):2161-4. 10.1016/j.athoracsur.2012.09.065

Briot K, Roux C, 2015. Inflammation, bone loss and fracture risk in spondyloarthritis. RMD Open 1(1):e000052. 10.1136/rmdopen-2015-000052

Caron T, Bransford R, Nguyen Q, Agel J, Chapman J, Bellabarba C, 2010. Spine fractures in patients with ankylosing spinal disorders. Spine (Phila Pa 1976) 35(11):E458-64. 10.1097/BRS.0b013e3181cc764f

Chock MM, Aho J, Naik N, Clarke M, Heller S, Oderich GS, 2015. Endovascular treatment of distal thoracic aortic transection associated with severe thoracolumbar spinal fracture. Vascular 23(5):550-2. 10.1177/1708538114560458

Coimbra R, Yang J, Hoyt DB, 1996. Injuries of the abdominal aorta and inferior vena cava in association with thoracolumbar fractures: a lethal combination. J Trauma 41:533-5.

Cooper C, Carbone L, Michet CJ, Atkinson EJ, O'Fallon WM, Melton LJ, 3rd, 1994. Fracture risk in patients with ankylosing spondylitis: a population based study. J Rheumatol 21:1877-82.

Cultrera F, Gamberini E, Iacono G, Turicchia GU, Agnoletti V, Tosatto L, 2017. Unstable thoracic spine fracture with aortic encroachment: A potentially fatal association and a suggested treatment. Int J Surg Case Rep 39:181-4. 10.1016/j.ijscr.2017.08.015

Domenicucci M, Ramieri A, Landi A, Melone AG, Raco A, Ruggiero M, Speziale F, 2011. Blunt abdominal aortic disruption (BAAD) in shear fracture of the adult thoraco-lumbar spine: case report and literature review. Eur Spine J 20 Suppl 2:S314-9. 10.1007/s00586-011-1732-7

Fazl M, Bilbao JM, Hudson AR, 1981. Laceration of the aorta complicating spinal fracture in ankylosing spondylitis. Neurosurgery 8(6):732-4.

Feldtkeller E, Vosse D, Geusens P, van der Linden S, 2006. Prevalence and annual incidence of vertebral fractures in patients with ankylosing spondylitis. Rheumatol Int 26:234-9. 10.1007/s00296-004-0556-8

Hitchon PW, From AM, Brenton MD, Glaser JA, Torner JC, 2002. Fractures of the thoracolumbar spine complicating ankylosing spondylitis. J Neurosurg 97(2 Suppl):218-22.

Inaba K, Kirkpatrick AW, Finkelstein J, Murphy J, Brenneman FD, Boulanger BR, Girotti M, 2001. Blunt abdominal aortic trauma in association with thoracolumbar spine fractures. Injury 32:201-7.

Kirshblum SC, Burns SP, Biering-Sorensen F, Donovan W, Graves DE, Jha A, Johansen M, Jones L, Krassioukov A, Mulcahey MJ, Schmidt-Read M, Waring W, 2011. International standards for neurological classification of spinal cord injury (revised 2011). J Spinal Cord Med 34:535-46. 10.1179/204577211X13207446293695

Klingberg E, Geijer M, Gothlin J, Mellstrom D, Lorentzon M, Hilme E, Hedberg M, Carlsten H, Forsblad-D'Elia H, 2012. Vertebral fractures in ankylosing spondylitis are associated with lower bone mineral density in both central and peripheral skeleton. J Rheumatol 39:1987-95. 10.3899/jrheum.120316

Lifshutz J, Lidar Z, Maiman D, 2005. Thoracic aortic pseudoaneurysm after spine trauma in ankylosing spondylitis. Case report. J Neurosurg Spine 2(2):218-21. 10.3171/spi.2005.2.2.0218

Lukasiewicz AM, Bohl DD, Varthi AG, Basques BA, Webb ML, Samuel AM, Grauer JN, 2016. Spinal Fracture in Patients With Ankylosing Spondylitis: Cohort Definition, Distribution of Injuries, and Hospital Outcomes. Spine (Phila Pa 1976) 41(3):191-6. 10.1097/BRS.0000000000001190
Montala N, Juanola X, Collantes E, Munoz-Gomariz E, Gonzalez C, Gratacos J, Zarco P, Fernandez Sueiro JL, Mulero J, Torre-Alonso JC, Batlle E, Carmona L, 2011. Prevalence of vertebral fractures by semiautomated morphometry in patients with ankylosing spondylitis. J Rheumatol 38(5):893-7. 10.3899/jrheum.100851
Omori K, Jitsuiki K, Majima T, Takeuchi I, Yoshizaw T, Ishikawa K, Ohsaka H, Tambara K, Yanagawa Y, 2017. Aortic Injury Due to Paragliding: A Case Report. Int J Sports Phys Ther 12:390-401.
Sambrook PN, Geusens P, 2012. The epidemiology of osteoporosis and fractures in ankylosing spondylitis. Ther Adv Musculoskelet Dis 4(4):287-92. 10.1177/1759720X12441276
Savolaine ER, Ebraheim NA, Stitgen S, Jackson WT, 1991. Aortic rupture complicating a fracture of an ankylosed thoracic spine. A case report. Clin Orthop Relat Res 272:136-40.
Schaberg FJ, Jr., 1986. Aortic injury occurring after minor trauma in ankylosing spondylitis. J Vasc Surg 4:410-1.
Stambough JL, Ferree BA, Fowl RJ, 1989. Aortic injuries in thoracolumbar spine fracture-dislocations: report of three cases. J Orthop Trauma 3:245-9.
Tiesenhausen K, Thalhammer M, Koch G, Schleifer P, 2001. [Traumatic aortic rupture in ankylosing spondylitis--a fatal complication]. Unfallchirurg 104:1101-3.
Ulu MA, Batmaz I, Dilek B, Cevik R, 2014. Prevalence of osteoporosis and vertebral fractures and related factors in patients with ankylosing spondylitis. Chin Med J (Engl) 127:2740-7.
Vosse D, Landewe R, van der Heijde D, van der Linden S, van Staa TP, Geusens P, 2009. Ankylosing spondylitis and the risk of fracture: results from a large primary care-based nested case-control study. Ann Rheum Dis 68:1839-42. 10.1136/ard.2008.100503
Ward MM, Deodhar A, Akl EA, Lui A, Ermann J, Gensler LS, Smith JA, Borenstein D, Hiratzka J, Weiss PF, Inman RD, Majithia V, Haroon N, Maksymowych WP, Joyce J, Clark BM, Colbert RA, Figgie MP, Hallegua DS, Prete PE, Rosenbaum JT, Stebulis JA, van den Bosch F, Yu DT, Miller AS, Reveille JD, Caplan L, 2016. American College of Rheumatology/Spondylitis Association of America/Spondyloarthritis Research and Treatment Network 2015 Recommendations for the Treatment of Ankylosing Spondylitis and Nonradiographic Axial Spondyloarthritis. Arthritis Rheumatol 68:282-98. 10.1002/art.39298
Weatherley C, Jaffray D, Terry A, 1988. Vascular complications associated with osteotomy in ankylosing spondylitis: a report of two cases. Spine (Phila Pa 1976) 13:43-6.
Werner BC, Samartzis D, Shen FH, 2016. Spinal Fractures in Patients With Ankylosing Spondylitis: Etiology, Diagnosis, and Management. J Am Acad Orthop Surg 24(4):241-9. 10.5435/JAAOS-D-14-00149
Westerveld LA, Verlaan JJ, Oner FC, 2009. Spinal fractures in patients with ankylosing spinal disorders: a systematic review of the literature on treatment, neurological status and complications. Eur Spine J 18(2):145-56. 10.1007/s00586-008-0764-0
Yoshioka Y, Morimoto Y, Sugimoto T, Arase H, Araki K, 2016. Blunt Abdominal Aortic Injury Associated with L2 Vertebral Fracture. Ann Vasc Surg 34:273 e1-3. 10.1016/j.avsg.2016.01.011

The authors report no conflict of interest concerning the material or methods used in the findings specified in this paper.

Correspondence: Neil Klinger nklinger@med.wayne.edu